

ANIMAL BLOOD
Clifford E Carnicom
Jan 27 2010

I am not offering any medical advice or diagnosis with the presentation of this information. I am acting solely as an independent researcher providing the results of extended observation and analysis of unusual biological conditions that are evident.

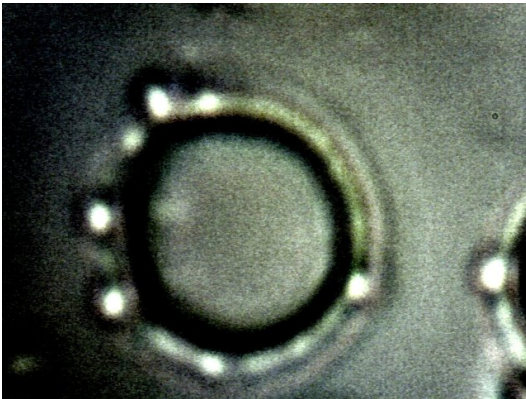
Samples of blood from two canines have been made available to me for examination. The age of one of the dogs is 11 years and the age of the other dog is unknown.

Both animals show the existence of the chlamydia-like organism within the blood and the serum in a fashion identical to that which has been repeatedly found in human blood samples. This particular organism is under extensive study and it is a dominant component of the biological research that is underway. This organism, along with three other forms (pleomorphic, encasing filament, erythrocytic) repeatedly described are central aspects of the so-called "Morgellons" condition.

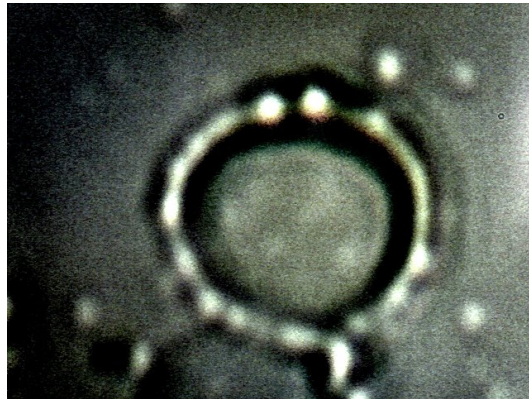This research reveals that the consideration of biological symptoms, structures and characteristics of the *Morgellons* condition must now be extended to include other life forms beyond that of the human.

At a minimum, this consideration now extends to the mammalian segment of the animal kingdom. There is additional research (external DNA examination and culture analyses) underway which suggests that this discovery may extend further to include the plant kingdom or the food supply; further examinations are required to clarify the initial findings.

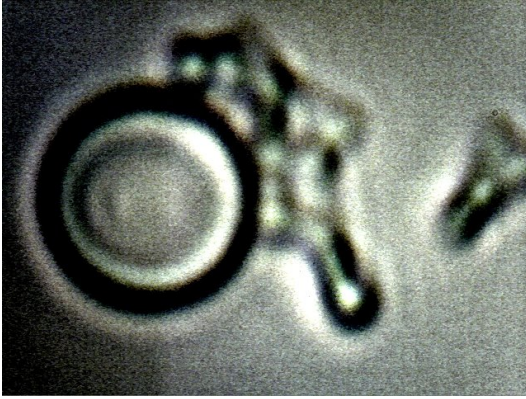
PHOTOGRAPHS:



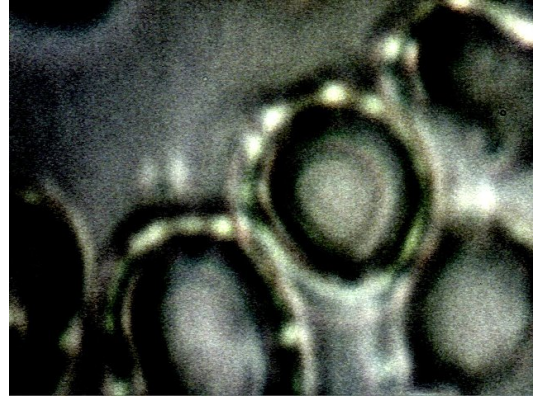An example of canine blood subjected to examination at high power under the microscope. The existence of the chlamydia-like organism that has been reported on extensively over several years on this site is evident. Several instances of the organism attached to the exterior of the erythrocyte wall are visible. Approx. magnification is 10,000x.



Additional instances of the chlamydia-like organism external to and attached to the exterior of the canine erythrocyte wall are visible. Please see [A Mechanism of Blood Damage](#) and [Live Analysis](#) for further information on human studies. This particular organism is a central focus by this researcher on the *Morgellons* conditions. Approx. magnification is 10,000x..



Additional instances of the chlamydia-like organism external to the canine erythrocyte wall are visible. Approx. magnification is 10,000x..



A sample of the blood of the 11 year old canine subjected to high magnification. Additional damage to the integrity of the erythrocytes of the 11 year old dog exists in comparison to the other sample. Approx. magnification is 10,000x.